

LAMINITIS IN DONKEYS



WHAT IS LAMINITIS?

Whole books have been written about laminitis - what follows is a brief summary.

The normal anatomy of the donkey foot depends upon a firm connection between the insensitive hoof wall and the sensitive 'quick' (tissue adherent to the pedal or toe bone). This is brought about by both tissues being folded into leaves or 'laminae' and interweaved so there is a large surface area in intimate contact (think of it like Velcro) – this is needed to withstand the downward pressure exerted by the weight of the donkey. All that stands between the normal donkey and a 'foundered' donkey (rotation or downward movement of the pedal bone) is that vital interlocking of tissue. When this connection is compromised the pedal bone loses its support. Now we understand so much more about this cripplingly painful disease we know that there are several different causes but all result in the same pathology – always painful, seldom reversible and sometimes fatal.

WHAT CAUSES THIS TO HAPPEN?

Potential causes of laminitis are:

1. An infection in any part of the body, e.g., womb or chest infections;
2. Excess weight being placed on one foot because the donkey has pain in the opposite foot;
3. Access to too much grass;
4. Access to cereal or other sugar rich feed;
5. Hormonal imbalances/disturbances.

Risk factors 1, 2, 3 and 4, have been well known for some time. Recent advances in our knowledge have revealed that **Equine Metabolic Syndrome** (similar to Type 2 Diabetes in humans), which results in the body not reacting as it should to the hormone insulin, is very commonly linked to laminitis. We also now know that **Cushings Disease** (a benign enlargement of part of the pituitary gland in the brain) can induce laminitis.

WHAT ARE THE SIGNS OF LAMINITIS?

Donkeys have a very stoical nature – they do not behave in the same way as horses when they have severe foot pain. A donkey will tend to lie down more than usual (fig 1) or adopt subtle weight shifting as it stands. Just as one's finger may really throb if it is inflamed/ infected so a donkey's pulses may be felt either side of the fetlock. The donkey may appear dull and we already know that *a dull donkey is a veterinary emergency!* Longstanding cases of front foot laminitis may

A dull donkey is a veterinary emergency!

result in loss of muscle over the shoulder area as the donkey attempts to take most of its bodyweight on the hind limbs (fig 2). Evidence of bouts of laminitis is revealed by 'laminitic rings' on the hoof wall. These can be distinguished from other 'event rings' (e.g. sudden diet change) because they are not parallel with each other but diverge towards the heels (fig 3).

Signs of laminitis in donkeys;



Fig 1 increased lying down



Fig 2 muscle wastage in shoulder area

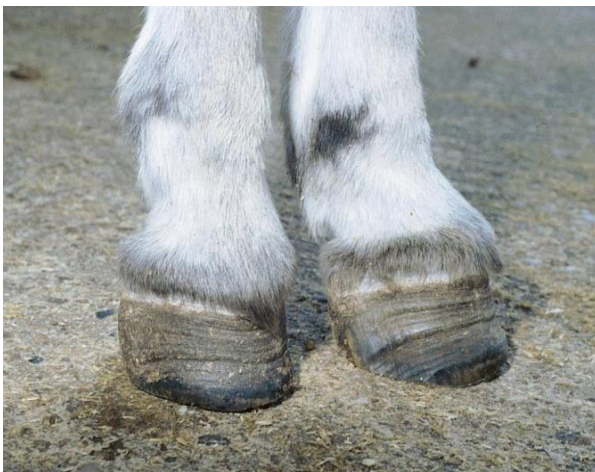

Fig 3 rings of abnormal hoof tissue which diverge towards the heels

Never leave a lame donkey until tomorrow. Lameness means pain! Prompt diagnosis and appropriate care can be a life saver.

WHAT CAN BE DONE FOR A DONKEY WITH LAMINITIS?

If you suspect your donkey has laminitis ensure he/she has access to a deep bed (shavings is much better than straw), easy access to food and water and ask your vet to visit **absolutely as soon as possible**. As with many diseases prompt treatment can make all the difference. Your vet will probably prescribe pain killers. The common one, 'bute' has to be given twice daily to donkeys. Whole sole supports (rather than frog supports as used in horses) may be advised. Xrays may be taken to see the extent of movement of the pedal bone. These pictures will be essential for the farrier to study for subsequent trimming. (Fig 4 – normal donkey foot, fig 5 a laminitic foot – note how the pedal bone has lost its parallel relationship with the front part of the hoof wall – the 'Velcro' has been ripped apart).

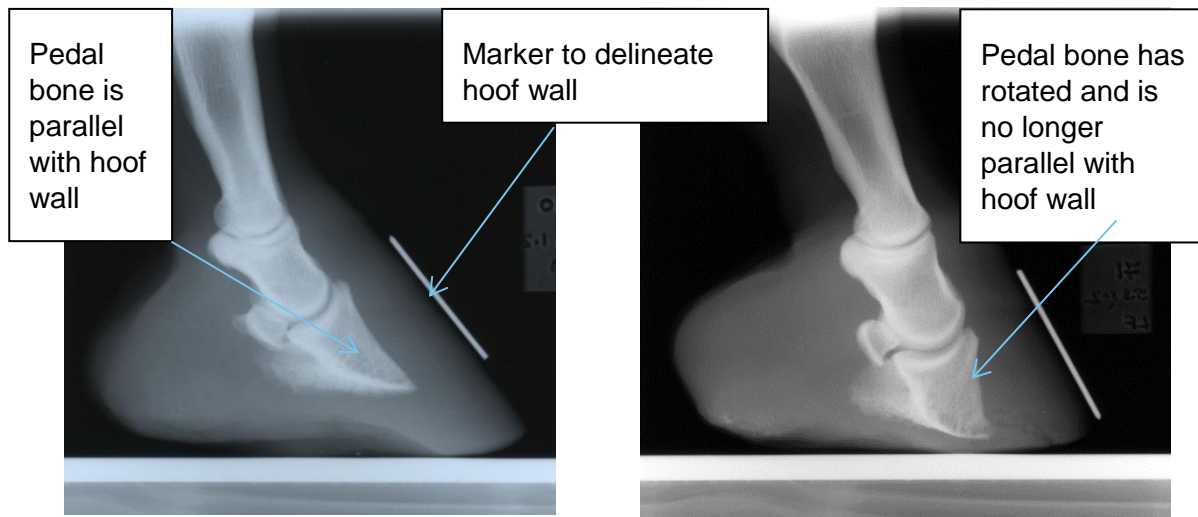


Fig 4 - X-ray of a normal donkey foot

Fig 5 - X-ray of a laminitic foot

HOW DOES FEEDING COME INTO THIS?

The best scenario is that correct diet and general management of your donkeys means you never see laminitis. A high fibre, low sugar diet, limited access to grass and rigorous weight management will go a long way to preventing this disease. For some donkeys even a few mouthfuls of grass can spell disaster and lush grass or grass that has a build-up of sugars as a result of dry weather or following a frost is particularly dangerous.

A diet of predominantly barley straw coupled with a vitamin/mineral supplement such as Top Spec Donkey Forage Balancer, and limited access to grass is ideal for healthy donkeys (obviously different rules apply if your donkey has dental disease but they *still* need a low sugar/high fibre diet).

The worst scenario is that a donkey suffers unremitting foot pain and its quality of life is such that euthanasia is the only kind option. The short striding, 'pottery' donkey is likely to be in considerable pain and if pain killers don't alleviate the condition then a responsible decision has to be made in the best interests of the donkey. There is nothing good about laminitis!

For further information on feeding donkeys with laminitis please see our 'Feeding the laminitic donkey' factsheet.

ACKNOWLEDGEMENTS

Author: Anna Harrison.

© The Donkey Sanctuary. All rights reserved 2016.

Published 2016.

THE DONKEY SANCTUARY

Slade House Farm, Sidmouth, Devon EX10 0NU

T [44] (0)1395 578222 F [44] (0)1395 579266 E enquiries@thedonkeysanctuary.org.uk

www.thedonkeysanctuary.org.uk

The Donkey Sanctuary was founded by Dr Elisabeth Svendsen MBE in 1969.

The Donkey Sanctuary (registered charity number 264818) and its sole corporate trustee, The Donkey Sanctuary Trustee Limited (Company number 07328588), both have their registered office at Slade House Farm, Sidmouth, EX10 0NU.

Incorporating: The Elisabeth Svendsen Trust for Children and Donkeys (EST); The International Donkey Protection Trust (IDPT).

WORKING WORLDWIDE